




## **BESA Research** Quick Guide





# BESA®

## 3D Maps

### Quick Guide

An introduction how to interpret 3D voltage and phase maps in the scalp EEG

#### Copyright and Trademarks

The BESA products and their documentation are copyrighted © 2018 by BESA GmbH. All rights reserved.

BESA® is a registered trademark of BESA GmbH, Graefelfing, Germany.

All other trademarks, brands and product names used in this guide are trademarks of the respective owners.

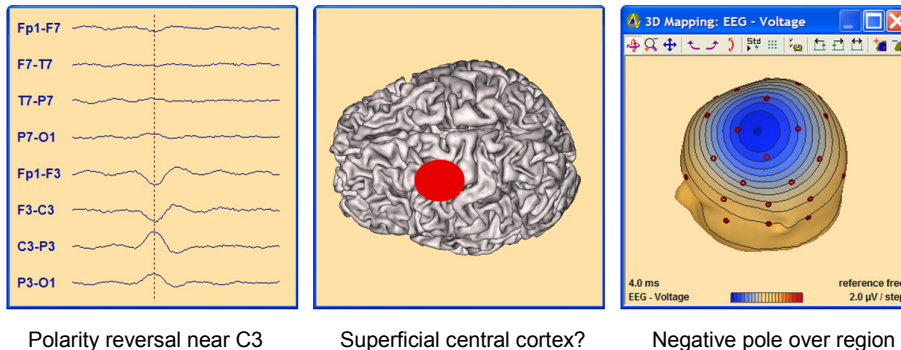
Author:	Michael Scherg
Document name:	BESA - Quick Guide on 3D maps
Revision number:	003
Revision date:	21 March 2018

# Table of Contents

<b>Table of Contents .....</b>	<b>2</b>
<b>1. When can we interpret a 3D voltage map? .....</b>	<b>3</b>
<b>2. How are 3D maps related to cortical activity? .....</b>	<b>5</b>
2.1. Sulcal versus superficial activity in the central region .....	5
2.2. Temporal lobe spikes - influence of the sublobar surfaces .....	6
<b>3. How can we interpret 3D maps? .....</b>	<b>7</b>
3.1. Consider the net cortical orientation .....	7
3.2. Use some easy rules to define the center of a 3D map .....	8
3.3. You may neglect the extent of the activated cortex .....	9
<b>4. Real 3D maps of interictal spikes in the scalp EEG .....</b>	<b>11</b>
4.1. Temporal lobe interictal spikes .....	11
4.2. Frontal lobe interictal spikes .....	11
4.3. Take your own decisions on real spikes .....	12
4.4. Suggested solutions .....	14

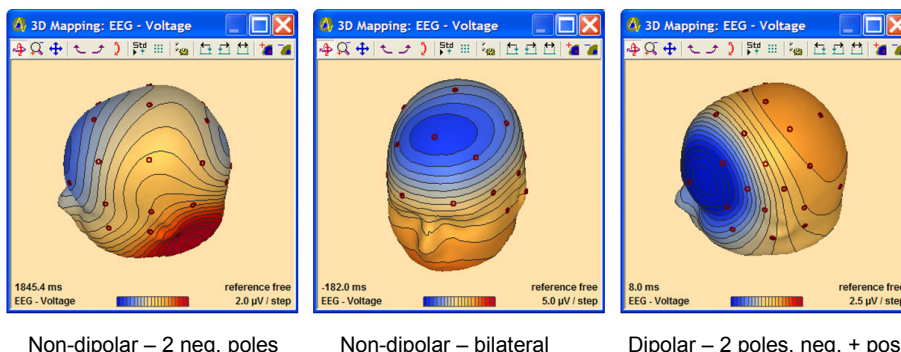
# 1. When can we interpret a 3D voltage map?

Traditional EEG training teaches to look out for polarity reversals to identify the negative peak, e.g. of interictal spikes. Often, it is assumed that this peak identifies the region of origin:



However, this concept is too simplistic and may often lead to misinterpretation as you will see below. Normally, the negative pole of a dipolar map is not exactly above the region of origin and may in fact be quite remote and even over the other hemisphere. Therefore, learn how to consider the whole topography including the positive pole to define the region of origin as shown below.

When using BESA Epilepsy or BESA Research in EEG review mode, you obtain a single 3D map when selecting a detected event or clicking on a spike peak or anywhere on the EEG traces. The 3D map automatically rotates to a viewpoint related to the center of the current EEG activity. Use the rotation buttons right/left, up-down in the mapping window for fast inspection of other viewpoints:



The 3D maps allow for an approximate visual localization of focal brain activity, i.e. if the EEG activity originates only in one circumscribed brain region. Focal brain activity produces a dipolar field on the scalp with 2 poles, a negative and a positive pole. The size of the poles depends on the location **and** orientation of the active cortical region as we will learn below. First, you need to check if the voltage map is dipolar:

**Rule 1: Check if map is dipolar, i.e. whether it has only one negative and one positive pole!**

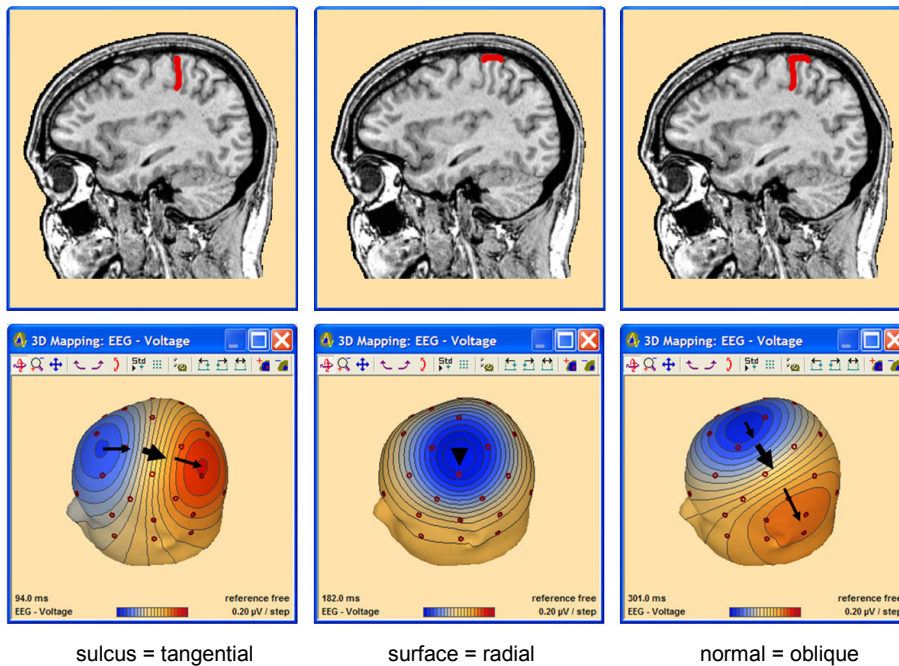
In the 3 maps above only the right map is dipolar, since there are 2 opposite poles. The negative pole over the left frontal scalp is more focally than the opposite positive pole. Maps with midline foci must always be checked carefully if they are bilateral (middle). Then interpretation is complicated and often obsolete.



## 2. How are 3D maps related to cortical activity?

### 2.1. Sulcal versus superficial activity in the central region

Consider a focal activity in the left central region and the related cortical folding. The activation can be in a sulcus, on the crown of a gyrus, or involve a patch covering both sulcal and superficial cortex:



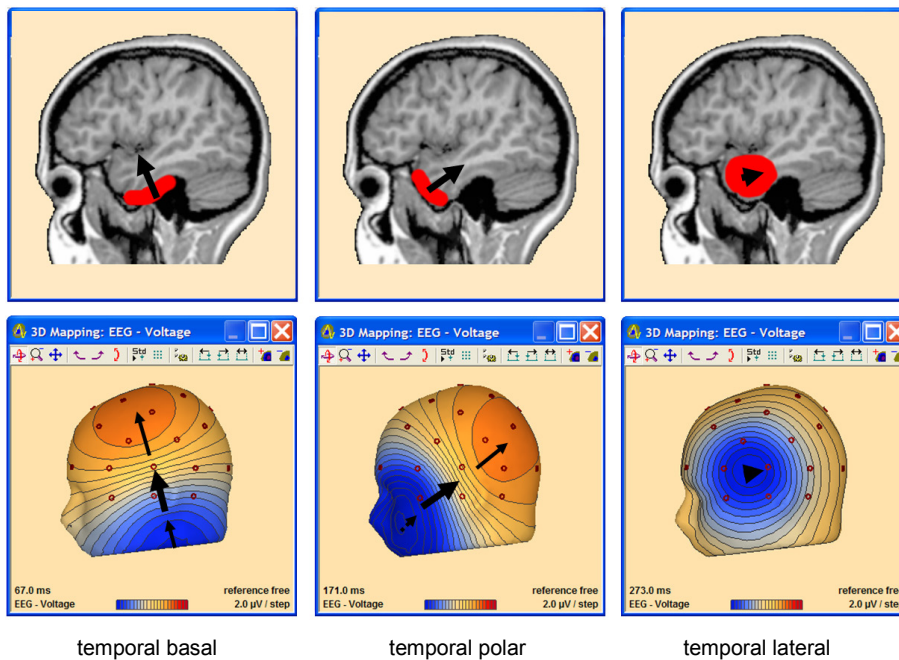
If we have the idealistic situation of an active fissure perpendicular to the cortical convexity, the voltage map is tangential (left). If only the crown of one gyrus (or a larger surface) is involved, the map appears radial (middle). Normally, both sulcal and superficial cortex are active and the map is oblique. The orientation of the map - thought of as a line in space pointing from the negative to the positive pole - is related to the net orientation of the active cortex. Thus, the map is more tangential the more sulcal cortex is active (left) and more radial the more superficial cortex is involved (middle, right; see also figure below).

In a tangential map (left), the center location of the active cortex is below the point on the scalp that is half-way between the poles. This corresponds to the area of maximum gradient (thick arrow). In a perfectly radial map (middle), the center location coincides with the peak of the negativity. The positive pole is on the opposite side of the head. It is weaker and more widespread.

A focal EEG map usually has a stronger and a weaker pole reflecting the net oblique orientation of the underlying active cortical patch (right). The center is closer to the stronger pole near the region with the largest gradients, i.e. where the equipotential lines are most dense.

## 2.2. Temporal lobe spikes - influence of the sublobar surfaces

Another important situation to understand are interictal spikes at the different cortical surfaces of the temporal lobe as shown below. Interictal spikes are cortex negative, i.e. the dipolar currents are flowing into the cortex. Thus, we can have initial spike currents into the basal or polar surfaces of the temporal lobe – common in mesial temporal lobe epilepsy – or into the anterior or posterior lateral cortex as well as downward currents on the upper surface of the temporal lobe within the Sylvian fissure:



On the left, the basal activation presents itself with a near-to-vertical 3D map with a stronger negative pole below the inferior temporal electrodes F9, T9, and P9. Depending on the amount of inferior lateral cortex involved, the positive pole resides on the same side near C3 (small involvement), near the vertex (middle) or even on the contralateral upper scalp (larger).

In the middle, the activation of the left polar region shows an oblique map with a negative pole on the cheek below the left eye. Depending on how much lateral polar cortex is involved, the negative pole may appear shifted more to the side, e.g. to F9, while the positive pole moves from posterior ipsilateral to the midline or contralateral. Depending on how much basal cortex is involved, the negative pole may be shifted to more inferior, e.g. to F11.

The right 3D map shows the typical radial pattern of a left temporal-anterior spike originating at the lateral cortical convexity. The corresponding positive pole is on the other side of the head. Only this pattern leads to the typical polarity reversal in the longitudinal bipolar montage.

The arrows in the basal and polar maps illustrate how to identify the center of activation (larger arrows) and the orientation of the underlying net dipolar current by connecting both poles (small arrows). The arrow in the lateral map (right) illustrates that the current flows inward into the lateral convexity of the temporal lobe.

As a temporal lobe spike evolves within the first 10-30 ms, several of these surfaces can become active simultaneously. For example, you may observe a shift of the negative peak from basal to polar and/or from basal to lateral. Then the 3D maps will just be a combination of the 3 basic map types shown above similar to the summation of the underlying dipolar currents into a combined equivalent dipole vector.

Whole head 3D mapping - based e.g. on spherical splines (Perrin et al. 1988) - is required to map these inferior negativities. Without inferior electrodes or the whole head 3D mapping, such temporal-basal and polar spikes may be easily overlooked.

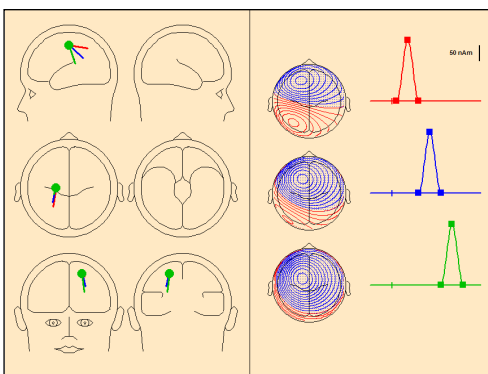


## 3. How can we interpret 3D maps?

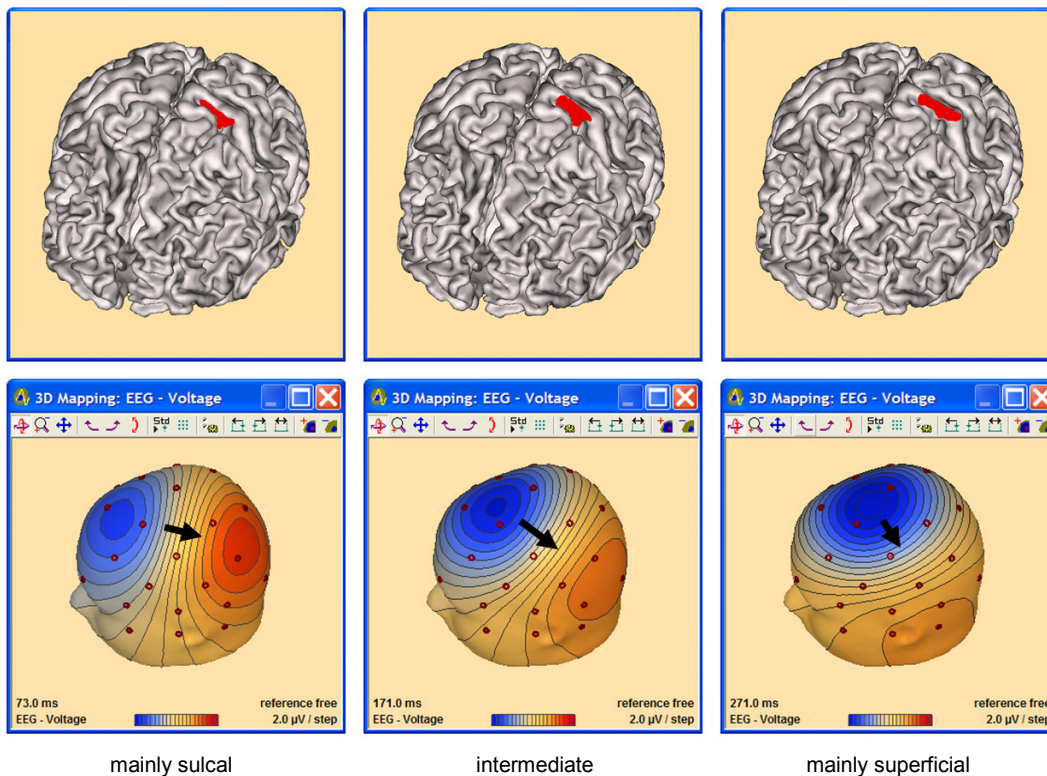
### 3.1. Consider the net cortical orientation

Let us consider a situation similar to the activation of the left central gyrus shown above and vary the proportion of active sulcal versus superficial cortex in a more moderate way. For better understanding we assume that the net orientation of the cortical activity does not change much in the horizontal plane (these orientation effects will be demonstrated further below) and center location is the same.

Using the free **DipoleSimulator** software (please download from [www.besa.de](http://www.besa.de)), the azimuthal orientation of the net source current was varied to reflect predominantly sulcal (red), intermediate (blue), and predominantly superficial (green) activities:



The corresponding cortical activities and 3D maps are illustrated below:



The arrows are all at the same position between C3 and Cz located above the simulated source center. The negative pole is more anterior in all cases. It is never exactly over the active region, even if the superficial activity dominates (right). Thus, we need to consider the whole 3D map to derive the center.

### 3.2. Use some easy rules to define the center of a 3D map

As already seen above, a typical focal EEG map has one stronger and one weaker pole. The origin lies below the region of largest gradients along the shortest scalp line connecting both poles. It is shifted slightly towards the stronger pole, if this is dominant (right).

Thus, we can derive a set of 5 rules how to estimate the approximate scalp location that is above the center of a focal brain activity:

**Rule 1: Check if map is dipolar, i.e. whether it has only one negative and one positive pole.**

**Rule 2: Consider the spatial orientation defined by both poles.**

**Rule 3: Draw a line mentally from the negative to the positive pole along the scalp.**

This line should follow the shortest route on the scalp (see arrows) and exhibit the highest voltage gradients, i.e. where the distance between equipotential lines is most narrow.

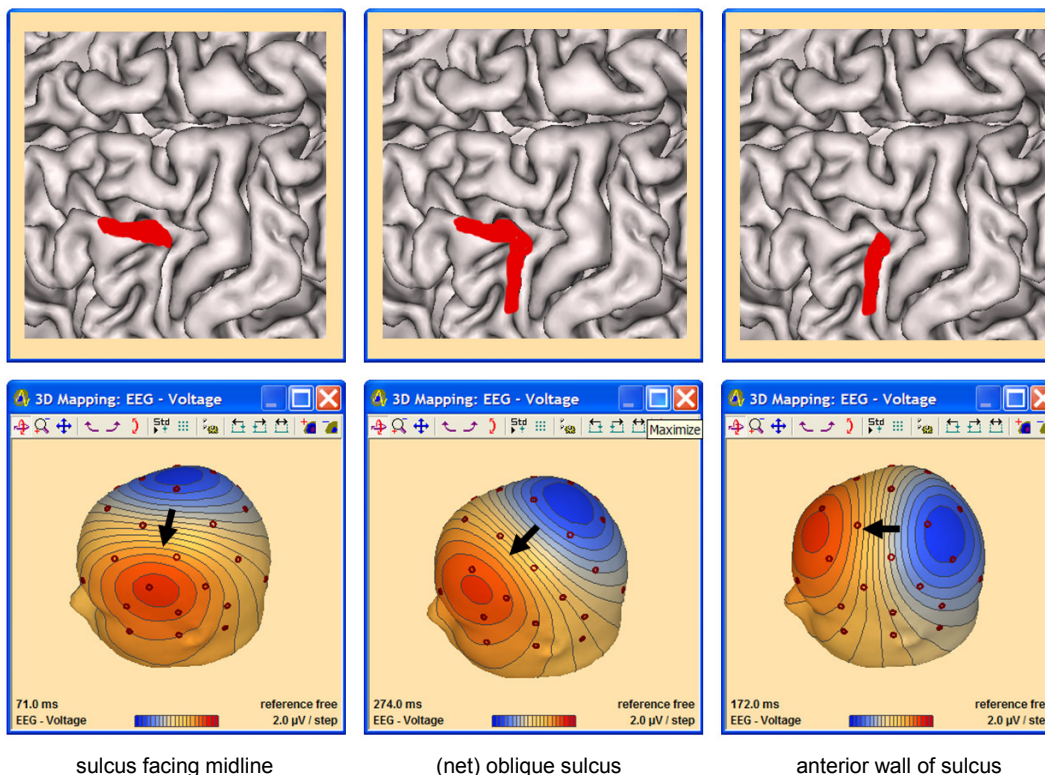
**Rule 4: Find the region of highest gradients.**

In a close-to-tangential map, the origin is below the region of highest gradient (near thick arrows). However, in oblique maps it is shifted more towards the stronger pole (right), more so if one pole is very dominant and if the weaker pole is on the other side of the head.

**Rule 5: Consider the relative strength of the negative and positive pole.**

Following these rules, we could plot the center arrows adequately in all the examples shown above.

Next, we want to simulate other activations in the left central region that are related to the 3-dimensional cortical convolution of a real brain. In the figure below, several sulcal activities at different aspects of the precentral sulcus have been assumed (only ~ 2 cm anterior and ~1 cm lateral to the previous generators; the interhemispheric fissure can be seen above extending horizontally):



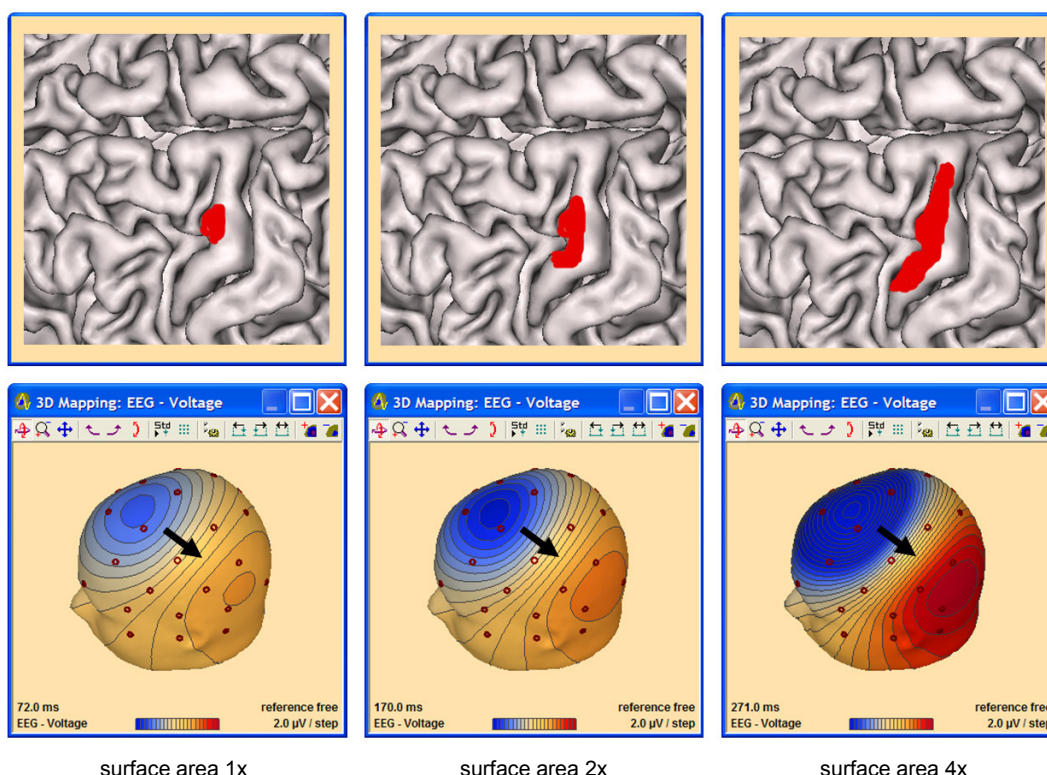
Interictal spikes are cortex negative, i.e. the current is flowing into the cortical surface. Thus, if a sulcus is nearly parallel to and facing the interhemispheric fissure (left), the current direction is from the opposite into the active hemisphere. This can create the so-called paradoxical lateralization, i.e. the negative spike peak is over the wrong hemisphere (left figure). Following our rules considering both poles and the gradients, we can localize more correctly (see arrow on the left and in the middle).

Depending on the 3-dimensional orientation of the active patch of cortex, the negativity can be anywhere on the upper head from posterior-parietal (right), midline (middle), contralateral (left), to anterior-frontal (see previous figure). Yet, if we use the above rules, we can well localize all these activities to the same left central region (cf. arrows).

In addition, considering the surface negativity of spikes we can identify that the anterior wall of the left precentral gyrus was activated in the right example of the above figure. Correspondingly, the anterior wall of the central fissure was activated in the right example of the figure above as opposed to the activation of the posterior wall in the left example of the previous figure. Both walls are just a few mm apart.

### 3.3. You may neglect the extent of the activated cortex

Next, let us observe what influence the size or extent of the activated cortex has:



For reasons of clarity, we assume in this simulation that the net orientation remains the same.

The surface area of the cortical patch increases from the left by a factor of 2 (middle) and a factor of 4 (right). Only the magnitude of the map changes by the same factors. There is no obvious change in the 3D pattern, since the equivalent center does not shift and orientation is stable. Principally, the center location on the scalp will not change. A larger area can merely lead to a slightly deeper center that would manifest itself in a slightly larger separation of the 2 poles, but the dipolar pattern remains similar. For an example, refer to the Hands-on Tutorial 1: 'Introduction to discrete source analysis' on [www.besa.de](http://www.besa.de).

Applied to epileptiform interictal spikes, an increased cortical area would lead to changes in EEG peak amplitude by similar factors.

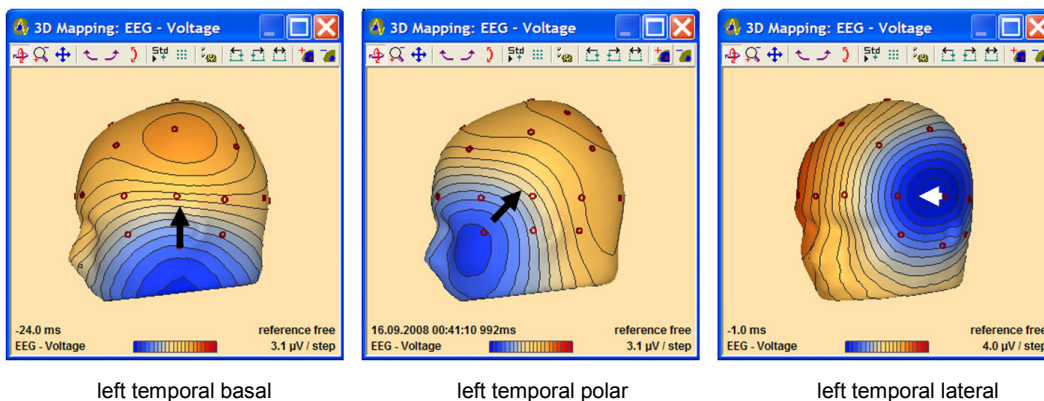




## 4. Real 3D maps of interictal spikes in the scalp EEG

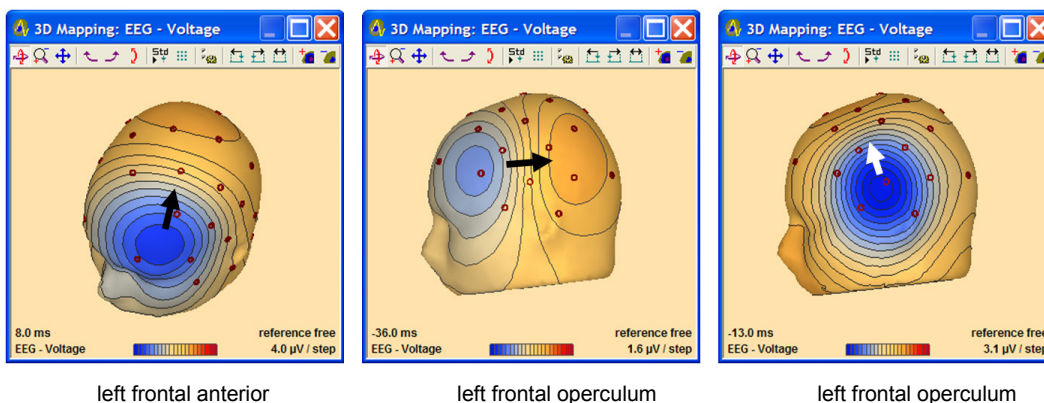
Below, we illustrate 3D maps from peaks or onsets of interictal spikes in the scalp EEG recorded from patients during long-term presurgical monitoring. The interpretations of the 3D spike maps are consistent with other clinical findings in these patients, e.g. seizure onset, brain lesions, source imaging etc. We gratefully acknowledge data and advice provided by Thomas Bast (University of Heidelberg; Epilepsiezentrum Kork), John Ebersole (University of Chicago), Pal Larsson (University of Oslo), and Nobukazu Nakasato (University of Sendai).

### 4.1. Temporal lobe interictal spikes



The left map center is near T9, the middle map center between F9, F7 and T7 indicating involvement of the polar and lateral anterior temporal sublobar surfaces. The right map center is near T7; the positive pole on the opposite side confirms the association with left lateral temporal.

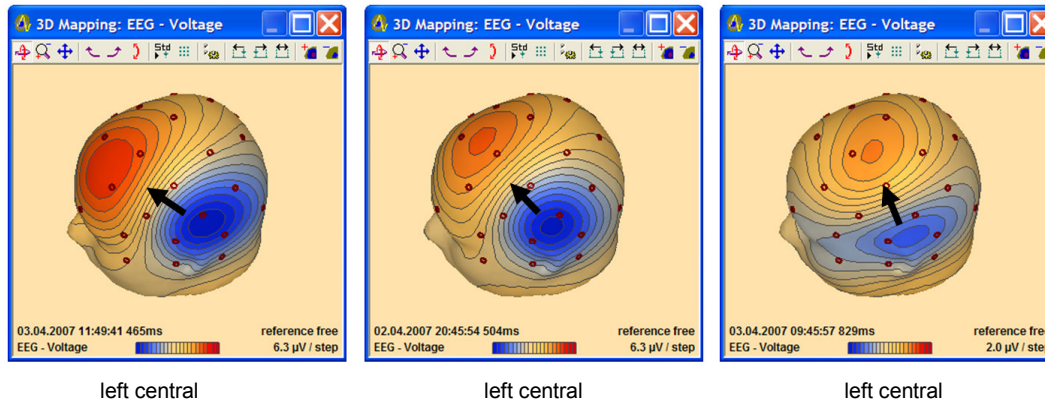
### 4.2. Frontal lobe interictal spikes



The left map is related to a left frontal anterior cortical dysplasia. The map center is near F3. The source is relatively deep because of the large separation of both poles.

The middle and right maps reflect the onset and peak topographies of an averaged rolandic spike. They exhibit the same center just above and ahead of T7. The vertex positivity in the right map shifts the center reconstructed according to our rules up above and ahead of T7, i.e. the same supra-sylvian region as identified by the onset map. The orientation of both maps suggests an onset of this rolandic spike at the posterior wall of the central sulcus (in the face area – current flows towards posterior) and propagation to the lateral and inferior (supra-sylvian) surface of the central gyrus (orientation is partly upward).

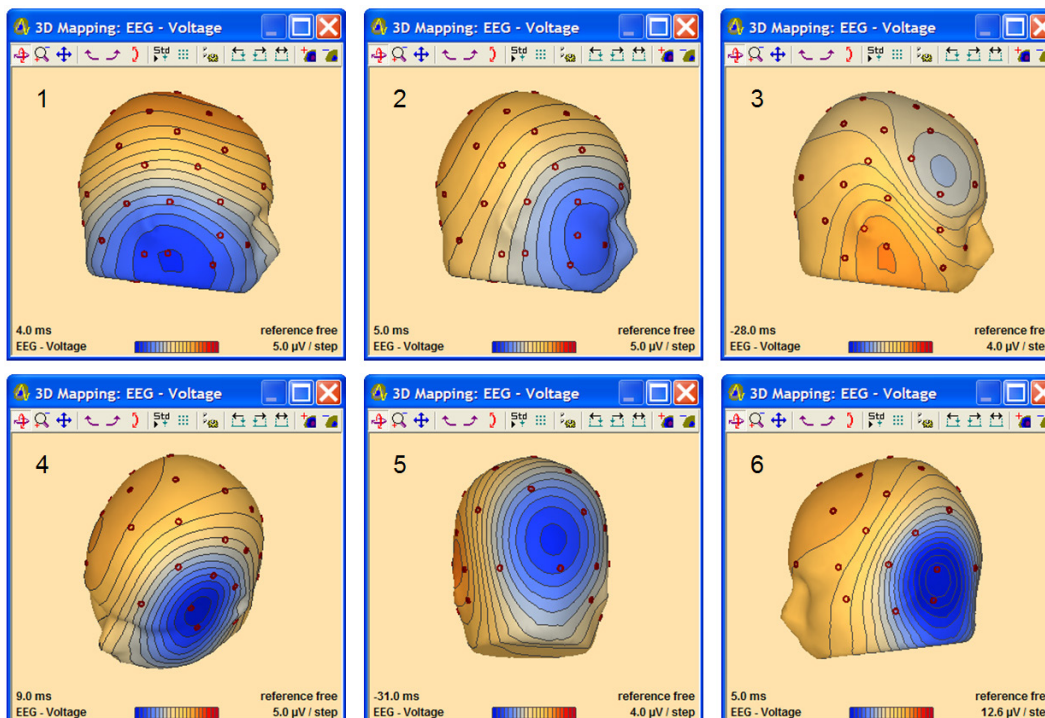
The comparison with the lateral temporal lobe map above shows a similar location of the negative pole in both cases. This illustrates that the negative pole alone is insufficient for visual localization.



Three left central spikes with different orientations from one patient. The negativity is not localizing. According to our rules, all spikes exhibit the same center just below C3 posterior to FC5.

### 4.3. Take your own decisions on real spikes

Finally, we suggest that you follow the rules outlined above to identify the side, the region of origin and, possibly, the sublobar surface in each of the following 6 interictal spike examples:



Examples 1-2 reflect 2 different spike types of one adult patient. Example 3 is from another adult; example 4 from a child, and examples 5-6 reflect the onset and peak maps of an averaged spike of another child.

You may label your solution by side, region, sublobar surface (e.g. L Tb) using the following abbreviations:

Side: R=right, L=left, B=bilateral

Region: F=frontal, FP=frontal-polar, C=central, P=parietal, O=occipital, T=temporal, TP=temporal-polar

Surface: l=lateral, b=basal, i=inferior, s=superior, a=anterior, p=posterior, m=mesial (2 surface letters may be used, if an oblique orientation suggests 2 lobar aspects to be involved).

A solution to this challenge can be found on [www.besa.de](http://www.besa.de) under Tutorials/Quick Guides. You are welcome to visit and confirm your success in this training on 3D maps.

## 4.4. Suggested solutions

This chapter includes the suggested solutions for the challenge according to the previous chapter.

1. R Tbl – patient having bilateral temporal spikes, right temporal basal spike involving basal and lateral surfaces.
2. R TPa – same patient, right temporal-polar spike, anterior surface
3. R TPs – different patient, right temporal-polar spike, superior surface (onset, downward orientation identifies anterior superior surface of TL in the Sylvian fissure, spike propagates to TPa within 10 ms)
4. L Fli – left frontal cortical dysplasia, orientation identifies lateral-inferior surface.
5. L Om – left occipital spike related to enlargement of left posterior ventricle. Map center and orientation identify mesial surface of left occipital lobe in interhemispheric cleft. This map represents the onset of the following spike peak (center is above O1, not near the negative peak above O2 – an example of the so-called paradox lateralization).
6. L Tpi – left temporal posterior-inferior. Map center and orientation identify lateral and inferior temporal cortex near the temporal occipital junction.





BESA GmbH  
Freihamer Str. 18  
82166 Gräfelfing – Germany

Phone + 49.89.89 80 99 66  
Email [info@besa.de](mailto:info@besa.de)  
Web [www.besa.de](http://www.besa.de)



The CE marking certifies that this product fulfills the essential requirements of the Medical Devices Directive MDD 93/42/EEC. The number 0197 represents the identification number of the Notified Body.

© Copyright 2018

